

徒手前庭眼球運動檢查

李薰華^{1,2} 張滋圃^{3,4}

¹台北醫學大學附設醫院神經內科

²台北醫學大學神經學科

³台中慈濟醫院神經內科

⁴慈濟大學醫學系神經學科

Q: 為什麼要對一個『暈』的病人，檢查眼球運動？『暈』不是和平衡比較有關係嗎？和眼球轉動有什麼關係？

A:

- ▶ 因為和『暈』密切相關的前庭系統，是眼球運動系統相當重要的一部分。
- ▶ 檢查「前庭眼反射(VOR)」對診斷前庭疾病至關重要。
- ▶ 其他的眼球運動系統，在腦部和中樞前庭系統，位置相近甚至重疊。所以檢查其他的眼球運動系統可以幫我們排除中樞病變。

BEDSIDE VESTIBULOOCULAR EXAMS

Types of eye movement

- Saccades
- Smooth pursuit
- Vestibuloocular reflex (VOR)
- Optokinetic response
- Vergence



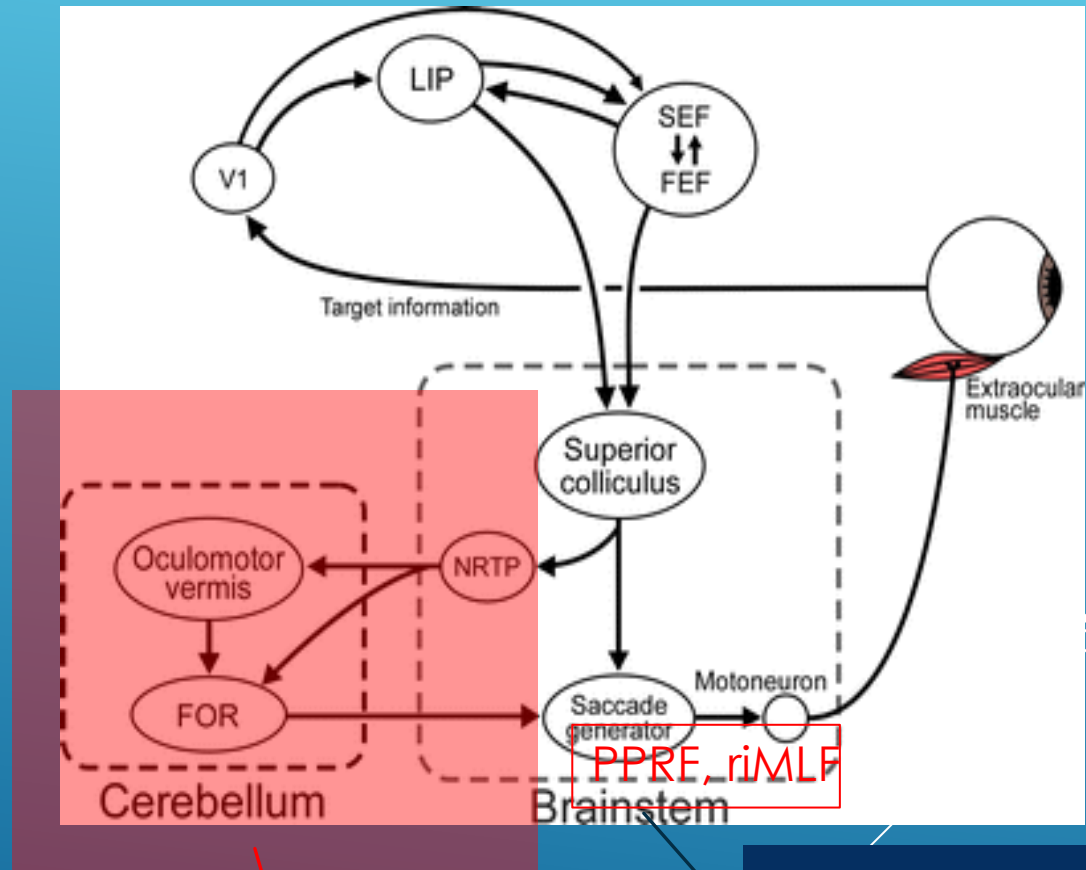
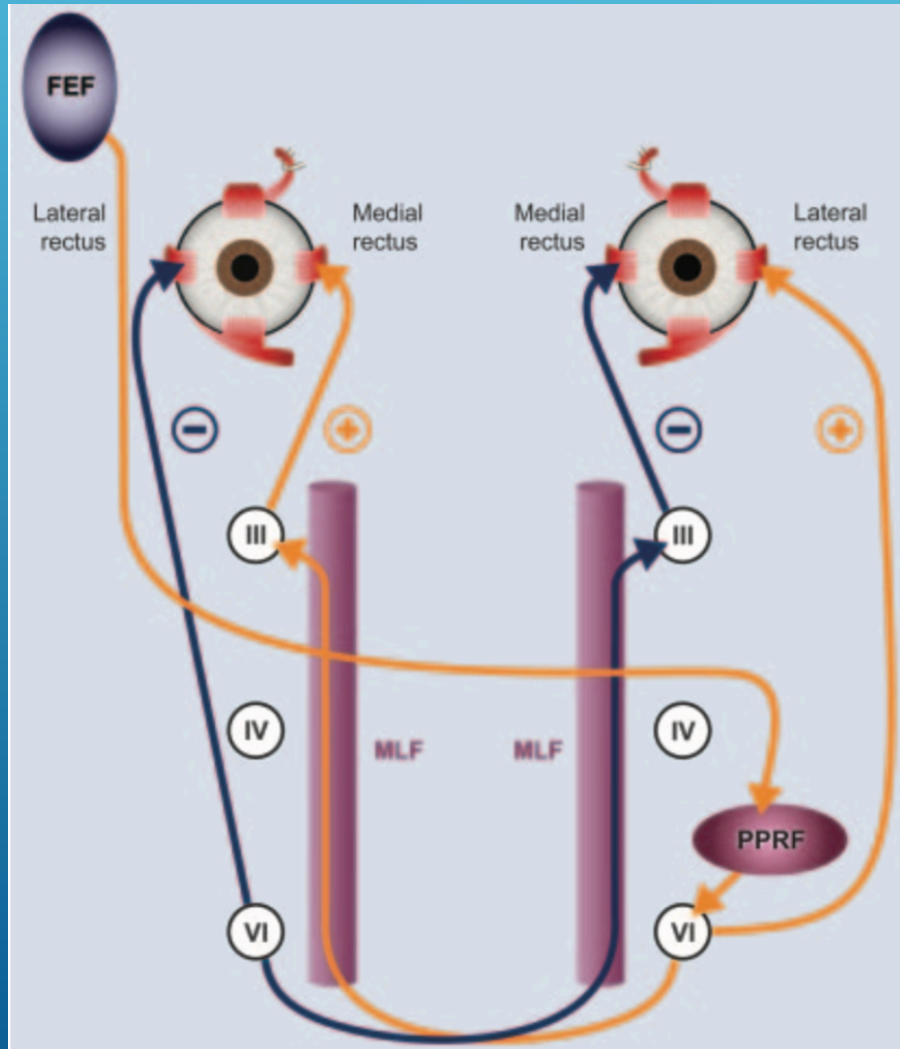
Vestibuloocular exams

- ▶ **Saccades**
- ▶ **Smooth pursuit**
 - ▶ VOR cancellation
 - ▶ Optokinetic nystagmus (OKN)
- ▶ **VOR**
 - ▶ Nystagmus
 - ▶ Head impulse test
 - ▶ Ocular Alignment (Test of skew deviation)
 - ▶ SVV bucket test

SACCADES

Saccades 操作示範

- ▶ Commended saccades
- ▶ Self-pacing saccades
- ▶ Anti-saccades
- ▶ Saccades initiation (latency)
- ▶ Velocity
- ▶ **Accuracy**
 - ▶ **Hypometric saccades**
 - ▶ **Hypermetric saccades**



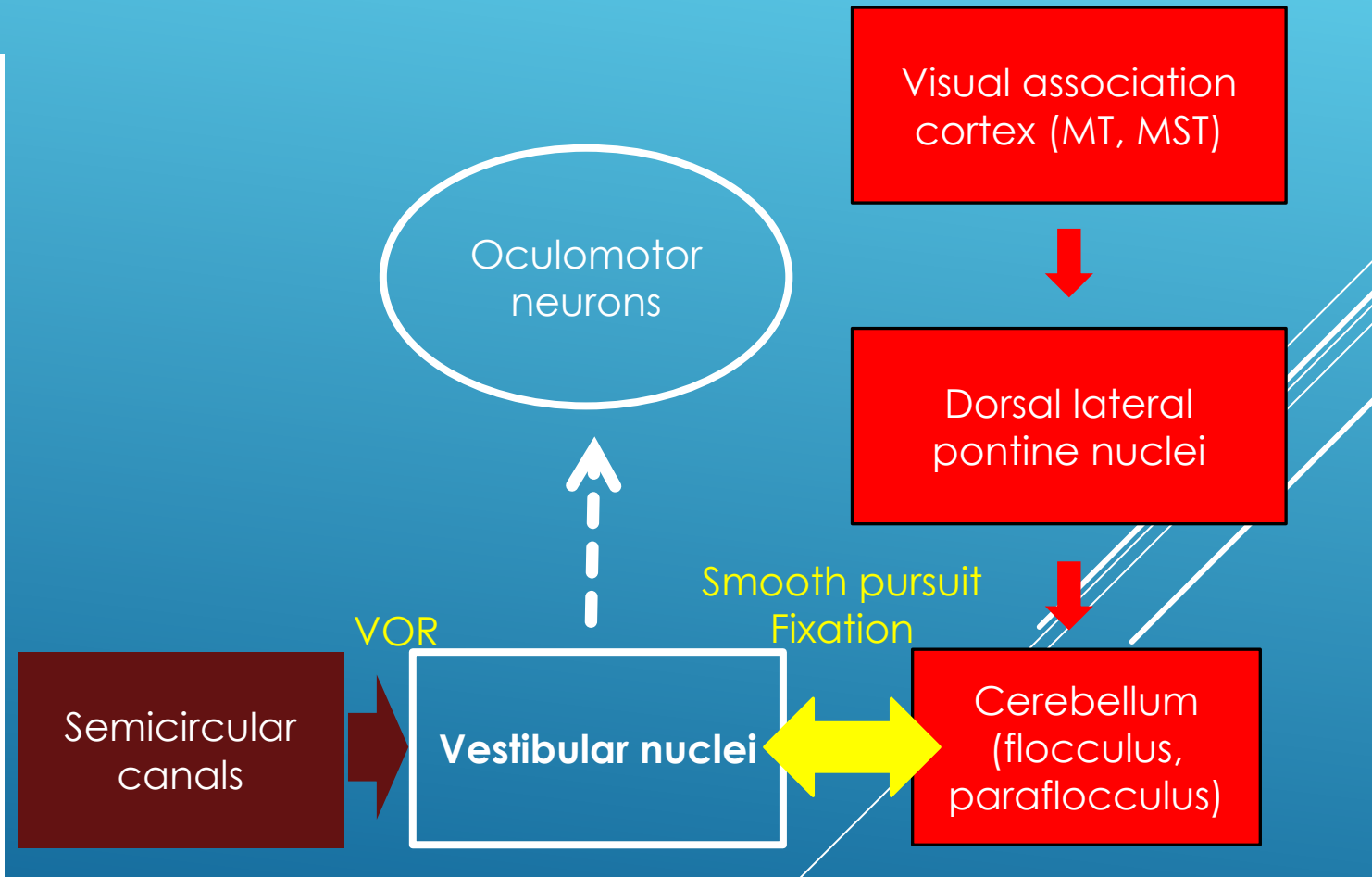
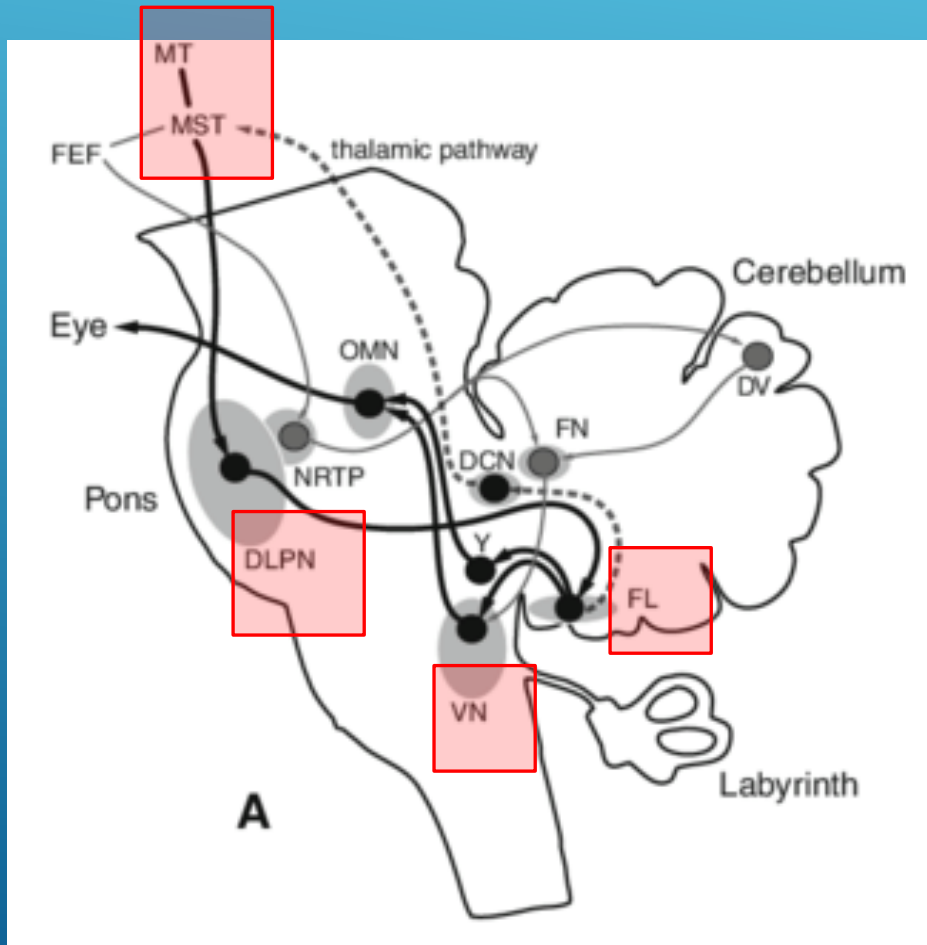
Saccadic accuracy

Saccadic initiation/velocity

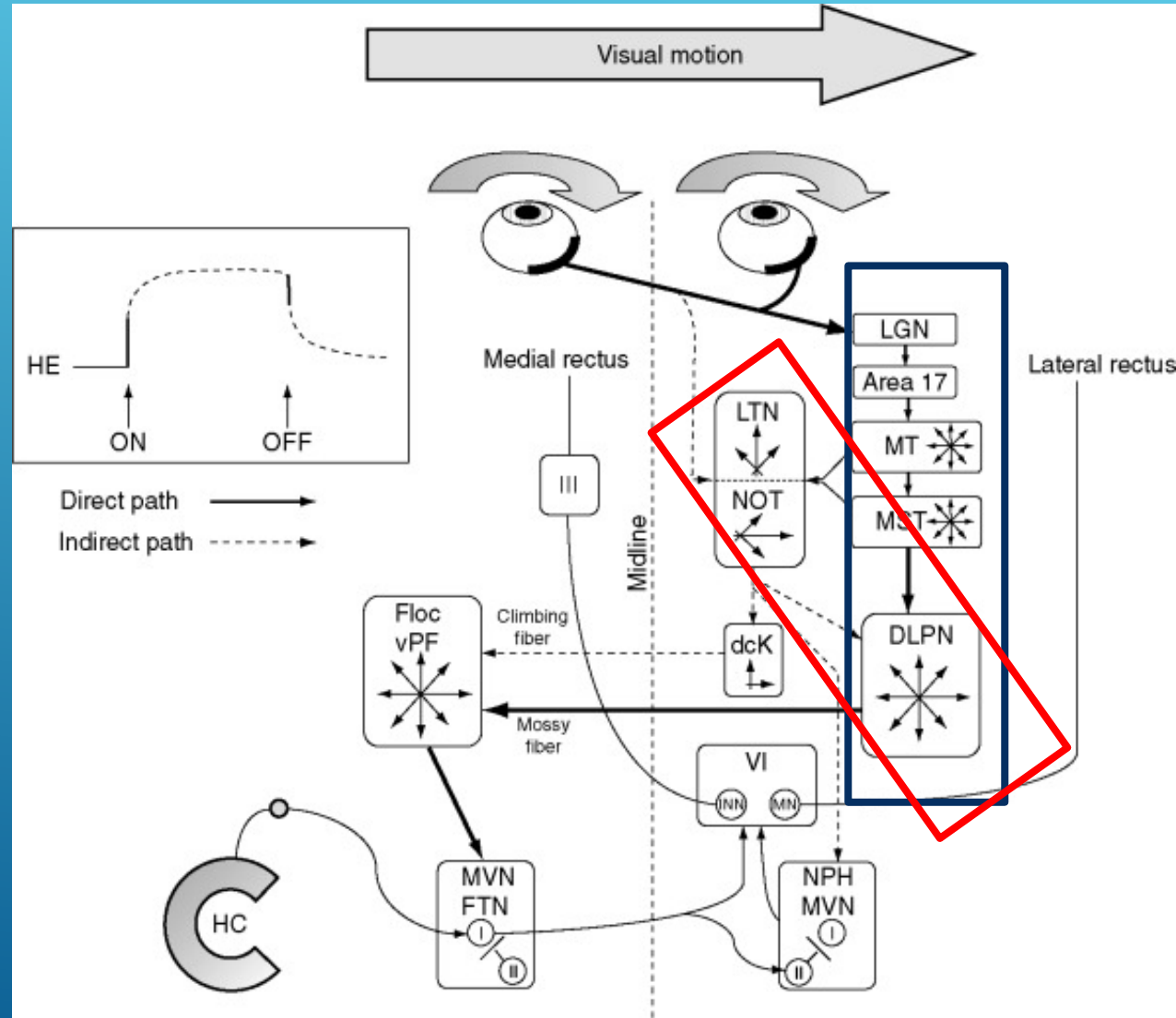
SMOOTH PURSUIT

- ▶ Smooth pursuit 操作示範
 - ▶ Saccadic pursuit
 - ▶ Asymmetric pursuit
 - ▶ Anticipatory saccades
- ▶ VOR cancellation 操作示範
- ▶ Optokinetic nystagmus (OKN) 操作示範
 - ▶ Stare nystagmus VS Look nystagmus

SMOOTH PURSUIT PATHWAY & VISUAL-VESTIBULAR INTERACTION



PATHWAY OF OKN



VOR

▶ Canal pathway

- ▶ Nystagmus (請見第二講題)
- ▶ **Head impulse test**


▶ Otolith pathway

- ▶ Test of skew deviation – check **ocular alignment**
- ▶ Test of subjective visual vertical (SVV) – **bucket test**

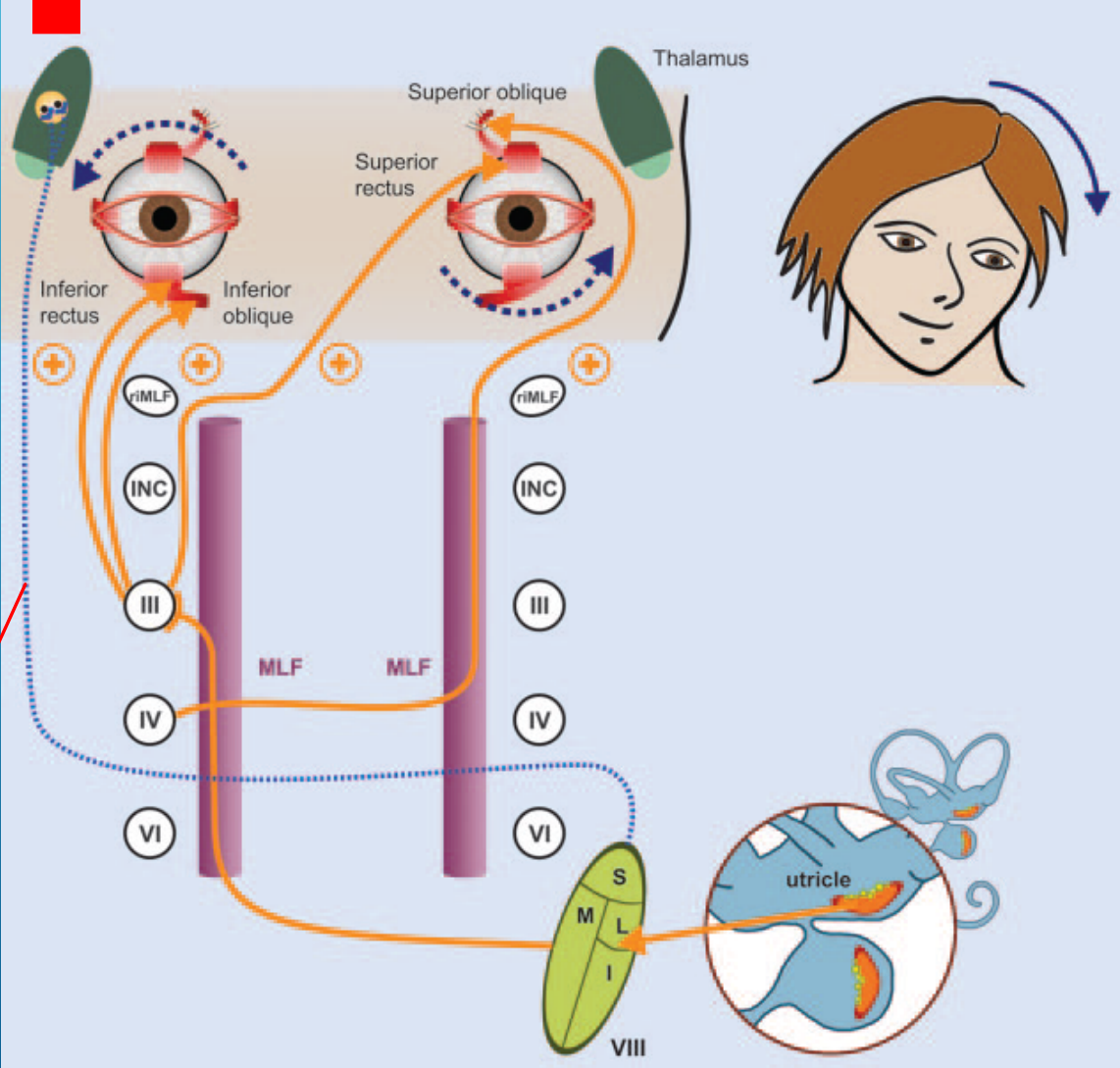
HEAD IMPULSE TEST

- ▶ Horizontal head impulse test 操作示範
- ▶ Prevent covert saccades
 - ▶ Randomize the head impulse direction
 - ▶ Randomize the head impulse tempo
 - ▶ Outward and inward head impulses
- ▶ Vertical-canal head impulse test 操作示範
 - ▶ LARP
 - ▶ RALP

OCULAR ALIGNMENT

- ▶ Cover test
 - ▶ Alternate cover test
 - ▶ Five directions of gaze
 - ▶ Maddox-Rod test
- 
- A decorative graphic consisting of several parallel white lines of varying lengths, slanted diagonally from the bottom right towards the top right, set against a blue gradient background.

Parietal insular vestibular cortex (PIVC)



Vestibulothalamic tract

SVV BUCKET TEST

- ▶ Deviation $< 2^\circ$: normal
- ▶ Deviation $> 3^\circ$: abnormal

