


100/7/24

第二十一屆南區頭痛讀書會
嘉基神內 許永居醫師



**CONQUER CHRONIC
MIGRAINE (I)**
FOCUS ON DIAGNOSIS

IHS Criteria for Migraine

- Episodic headache lasting 4-72 hours, attack >5 times, with:

Any 2 of:

- Unilateral
- Throbbing
- Moderate to Severe
- Worsened by Movement



Any 1 of:

- Nausea or vomiting
- Photophobia & phonophobia

- R/O other organic brain lesion



頭痛學始於MIGRAINE,
終於MIGRAINE

100/7/24 南區頭痛讀書會

- From Episodic to Chronic Migraine
 - Migraine and Vertigo
 - Misdiagnosis of Migraine
-
- Cases Report
 - Aura
 - Pediatric

In Neurologic Clinics...

- 病人: 醫生, 我的頭很痛~
- 醫生: 是喔, 痛多久了?
(心裡OS: “甘唔?”)



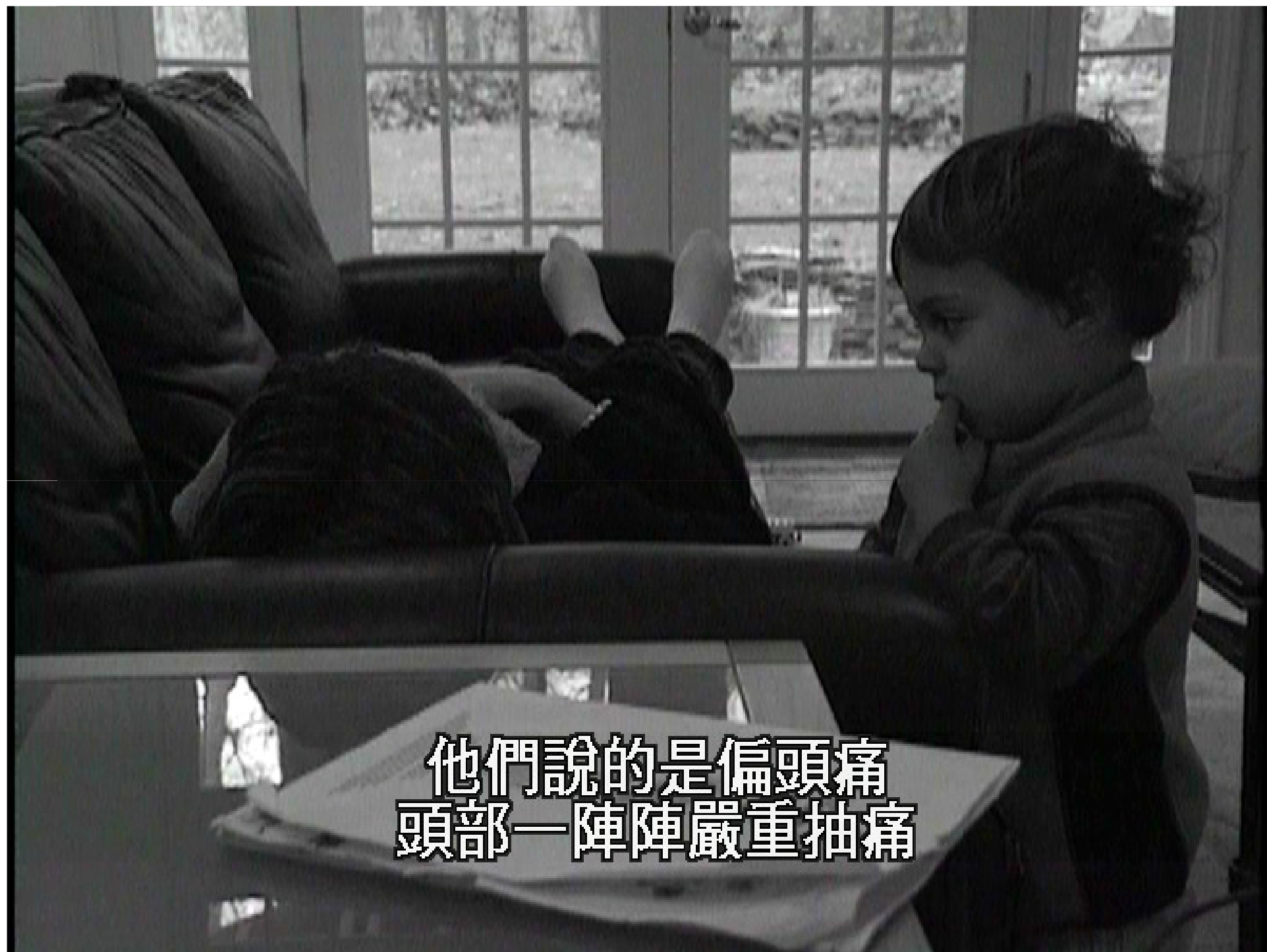

28 Million Americans

1 in 4 Households

women suffer 3 times
as often as men

twice a week
偏頭痛發作之頻繁
一週會有兩次

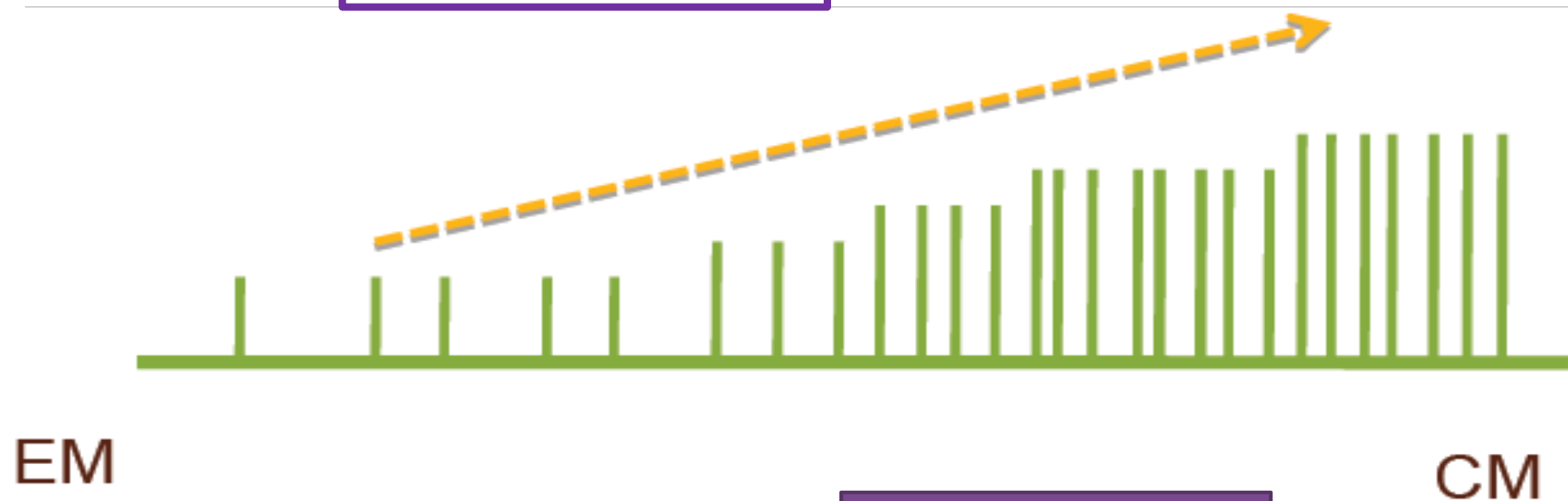


他們說的是偏頭痛
頭部一陣陣嚴重抽痛

$\geq 75\%$ CM experienced EM

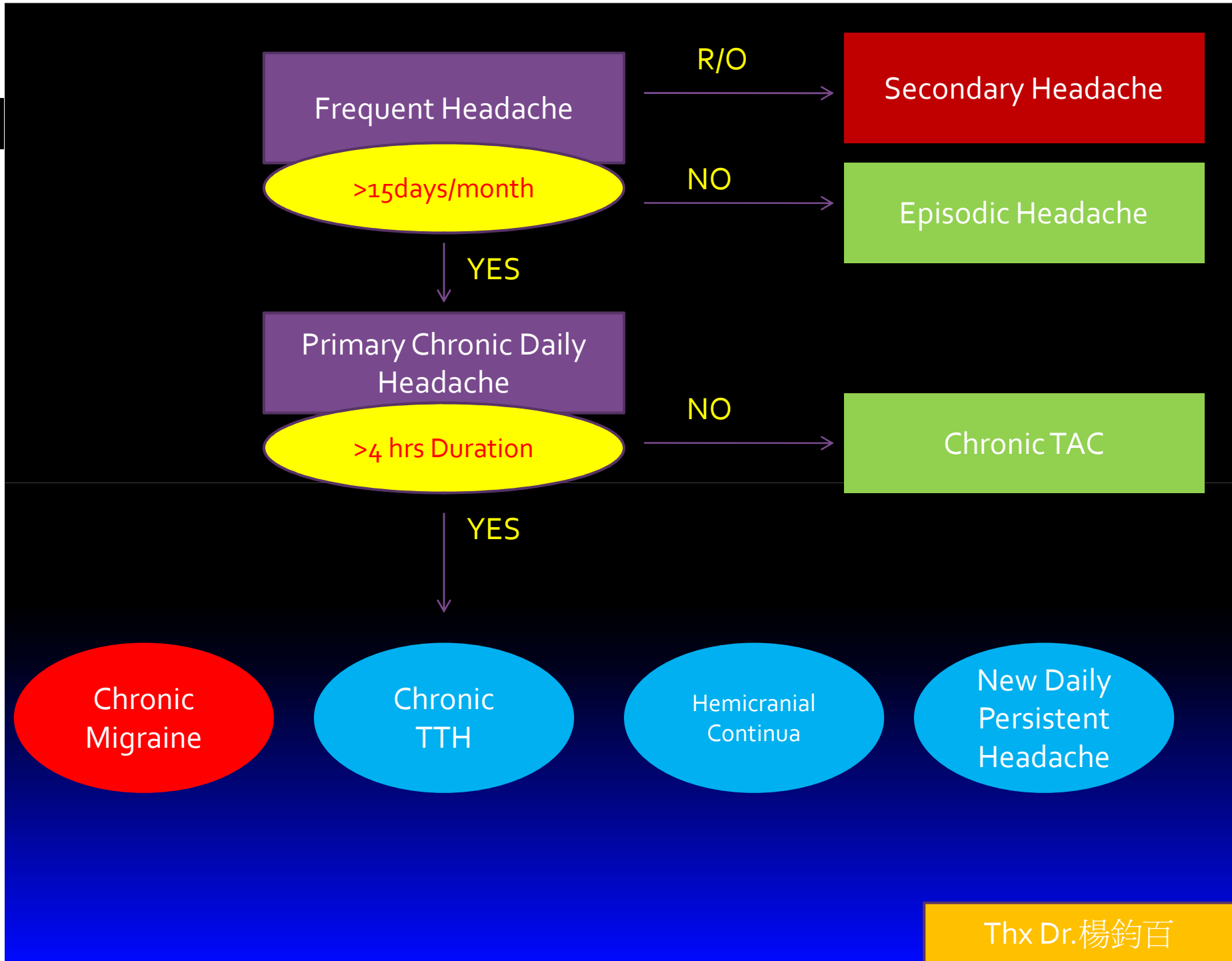
Less nausea/vomiting
Less throbbing ...

transformation



Thx Dr.楊鈞百

Headache. 2000;40:306-310.




Thx Dr.楊鈞百



A composite image featuring a person on the left holding their head in pain, and a background on the right filled with numerous white, round pills. A purple rounded rectangle in the top left corner contains the text 'Medication Overuse Headache'.

Medication Overuse
Headache

但藥效一過, 頭痛重新反擊



Migraine and Vertigo



Migraine and Vertigo

TABLE 4. Central Causes of Dizziness

1. Cerebrovascular disorders
2. Migraine
3. Multiple sclerosis
4. Central positional vertigo/nystagmus
5. Epilepsy
6. Craniocervical junction disorders
7. Neoplastic: primary, metastatic or paraneoplastic
8. Inherited ataxias
9. Psychophysiologic
10. Global cerebral hypoperfusion and hypometabolism
11. Neurodegenerative disorders: parkinsonism, normal pressure hydrocephalus
12. Posttraumatic dizziness
13. Toxic: alcohol, Cu, Hg, talium, lead, organic solvents, drugs (diphenylhydantoin, barbiturates, primidone, carbamazepine, 5-fluorourasil, methotrexate, piperazine nitrofurantoin, lithium)

- a. Basilar-type migraine
- b. Benign paroxysmal vertigo of childhood
- c. Migrainous vertigo (or vestibular migraine)

Diagnostic challenges in headache

Migraine as the wolf disguised in sheep's clothing



以偏頭痛呈現的單一漿細胞瘤--案例報告

文、圖/林上倫 蘇峻民 謝安臺* 錢尚道** 許競文***

國軍高雄總醫院外科部
內科部* 病理部** 門急診部***

案例報告

病人為46歲幼稚園女老師，過去無任何系統性疾病史，無任何手術紀錄，嗜喝咖啡(每日至少200 mL)，居住在高雄市的某工業區，生活正常，無特殊家族病史。主訴為就診前一個月，左側前額開始出現一處皮脂囊腫，並感覺到左側前額處有跳動感的鈍痛，痛感會蔓延到左耳耳後，疼痛頻率為每日至少10次，每次疼痛維持1到10秒鐘，發作的時候會合併浮浮沉沉的頭暈症狀，曾赴不同診所拿兩種以上止痛藥以及抗生素合併服用，也無法改善症狀。門診就醫時，理學檢查發現，左側前額頭皮有一處約2.5×2.5×0.5公分大小的腫塊，合併有嚴重壓痛感；經病人同意後，執行該病灶切除手術；手術中，以器械觸扣發現，病灶的底部有蝕骨變化(osteolytic change)，遂將切除後的病灶並刮取蝕骨處組織化驗，病理切片中，病灶(頭皮腫塊)呈現為皮脂腺囊腫(圖1)，蝕骨處組織則呈現大量的漿細胞在顱骨(圖2)中，而組織免疫化學染色發現漿細胞中只含κ輕鏈免疫球蛋白

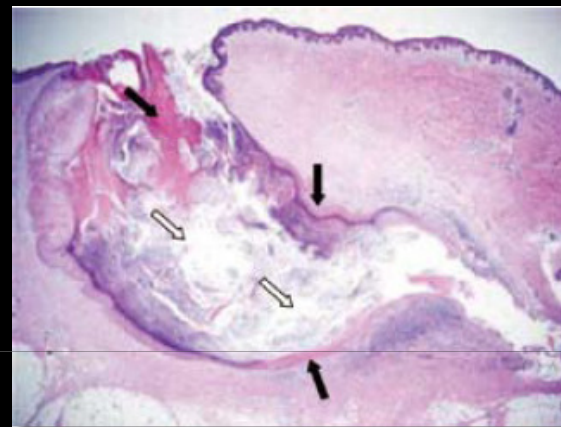


圖1 可見上皮囊腫有厚壁，內含皮脂腺(空心箭頭)，與豐富的角質成分(實心箭頭)(HE染色40X)

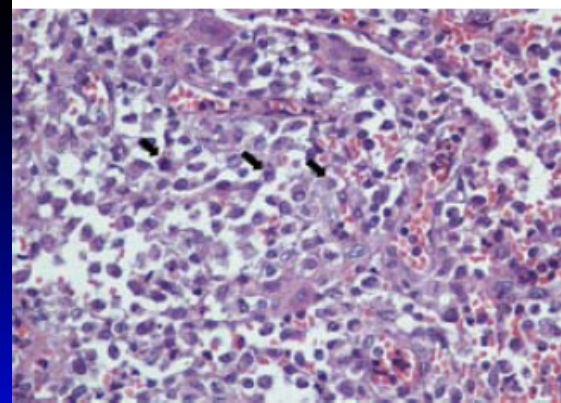


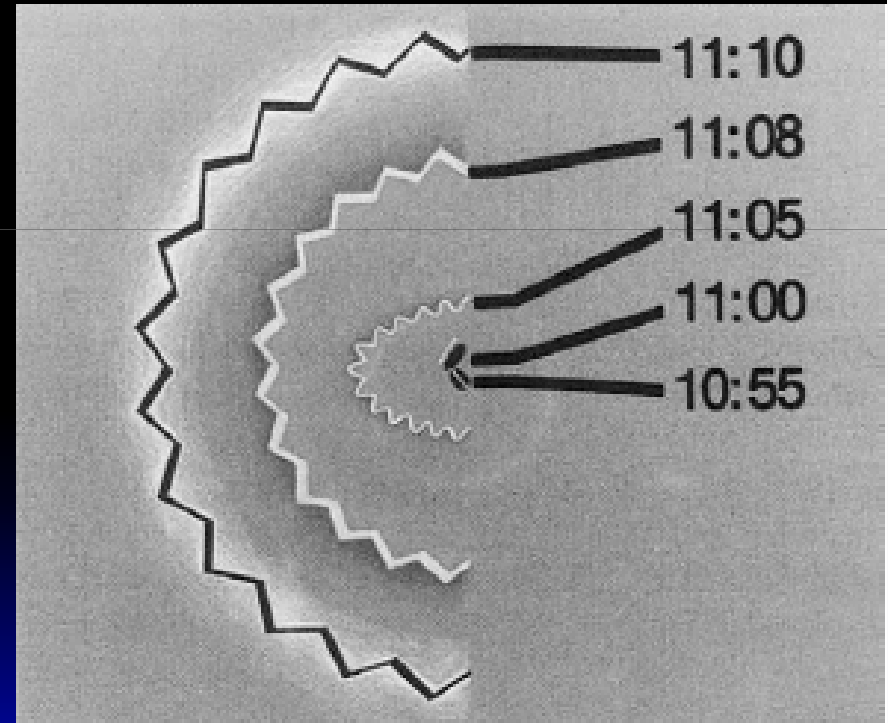


圖2 可見大量異常增生、呈現車輪狀的漿細胞(實心箭頭)(HE染色200X)



Visual Aura




THE ONSET OF MIGRAINE



FIRST WARNING

TWO MINUTES LATER

FOUR MINUTES LATER



SIX MINUTES LATER

EIGHT MINUTES LATER

NORMAL IN THREE MINUTES

VIOLENT HEADACHE FOLLOWS

EVE BENJAMIN 1985




Click to **LOOK INSIDE!**



Migraine Art


The Migraine Experience from Within



Klaus Posill and Derek Robinson



小孩子和青少年的頭痛問題
完全沒受到應有的重視



我知道偏頭痛快發作了
因為聽到敲擊聲